

Mechano-electric patterns during craniosacral osteopathic diagnosis and treatment

1979.07

JOHN E. UPLEDGER, D.O., F.A.O.
East Lansing, Michigan
ZVI KARNI, PH.D., D.S.C.
Haifa, Israel

Cranial osteopathic manipulative diagnosis and treatment is associated with palpatory sensations perceived by the cranially oriented osteopathic physician at various locations on the patient's body. The nature of these palpatory sensations ranges from smooth, regular, and rhythmic to quick, jerky and/or irregular motion. A study of mechano-electric measurements performed on patients in an inactive state of the body shows that distinct strain gauge, electrocardiography, electromyography, and integrated-electromyography patterns correspond with each one of the palpatory sensations. This correlation far exceeds random probability.

Motions that are detectable by palpation of individual cranial bones and/or of the entire cranial vault are associated with similar palpable motions at other locations on the body.¹⁻³ However, the cranium and the sacrum were used in this experiment because the motion is most apparent in these two areas. The nature of the physician-perceived sensations is variable. It ranges from a smooth, rhythmic motion which ebbs and flows and occasionally ceases entirely, to a quick, jerky or vibratory motion which may be quite irregular. The motions can be represented mechanically by a single, narrow band-width amplitude (Fig. 1a), by multiple amplitudes with varying frequencies (Fig. 1b), or by a form of a step function (Dirac's function) (Fig. 1c). In the first two instances, the baseline remains unchanged; in the case of step function, a change is indicated in the baseline for a limited time period (T_c) which is attained either instantaneously (Fig. 1c) or gradually (Fig. 1d).

The purpose of this research was to determine whether there were correlations between selected mechano-electric parameters (monitored at various regions of the body) and the physician's impressions of the changes in craniosacral motion (mechanics) during craniosacral diagnosis and treatment. The results indicate that almost every perceived change in craniosacral motion (mechanics) reported "blind"* by the physician has its unique counterpart in the mechano-electric changes in patterns recorded from other locations on the patient's body.

The character of the recorded mechano-electric patterns was *not* dependent on voluntary muscle activity of the patient, nor was it attributable to changes in the contact sites on the patient's body by the physician's hands.

Unless otherwise indicated, all recordings were made with the patient in a relaxed state. However, when voluntary muscle action did occur, it was indicated on the tracings.

Materials and methods

The mechano-electric patterns in Figure 1 were extracted from the recorded monitoring of the time variations of mechanical strain and of electric potentials of the skin at different loci on the patient's body during the cranial diagnosis and treatment. In the preliminary experiments, six- and eight-channel tracings were recorded. Later, however, as the multi-channel record became correlated with the perceived palpatory sensation, the recording was reduced to four channels, which was easier for the observer to handle and interpret.

The four channels included at least one strain

*The experimental facility was physically arranged so that the physician (Dr. Upledger) was unable to visualize the recordings as they were made. All notations were made in a timely fashion on the graph by the scientific observer (Dr. Karni) as the physician's impressions were verbally communicated. The scientific observer did not offer any verbal cues to the physician. Usually, the mechano-electric pattern changes preceded the verbal communications by approximately a second. This sequence of events rules out any obscure possibility that the patients could have responded "bioelectrically" to verbal cues given by the physician as his impressions were reported.

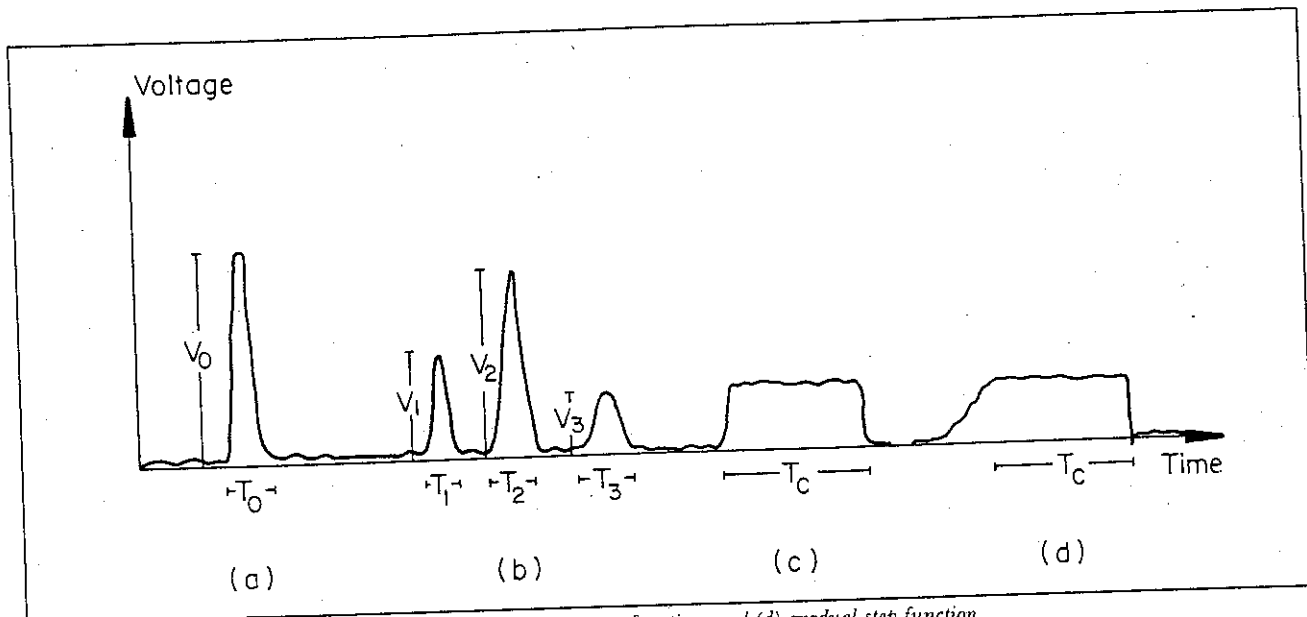


Fig. 1. Modes of motion amplitudes: (a) single, (b) multiple, (c) step function, and (d) gradual step function.

gauge, a unipolar ECG rhythm strip, and at least one I-EMG measurement. The standard arrangement was as follows: (1) a single strain gauge placed over the palpable pulse immediately below the inferior costal margin which monitored the patient's respiratory activity and the arterial pulsations; (2) a unipolar ECG rhythm strip; and (3) two EMG electrodes placed bilaterally and symmetrically on the anterior thighs. When our attention was focused upon respiratory activity, the following arrangement was used: (1) two strain gauges placed symmetrically and bilaterally just below the inferior costal margins; (2) a unipolar ECG rhythm strip; and (3) a single anterior thigh EMG. Sometimes both arrangements were applied to the same patient during a single treatment. The change from one arrangement to the other required only a few seconds.

The strain measurements were taken using Peekel electrical-resistance, high-extension rubber strain gauges type 20S.⁴ These gauges possess a maximum

extensibility of 20 percent and a maximum compressibility of 15 percent. Gauge specifications are as follows: overall dimensions, 46 × 17 mm. (1.80 × 0.69 inches); active length, 13 mm. (0.51 inches); electrical resistance, 119.5 ohm ± 0.2 percent; gauge factor—static extension, -0.0136 ± 2 percent; gauge factor—static compression, +0.0182 ± 2 percent. There is a negative gauge factor because of its construction; the resistance wire undergoes a compression when a positive strain (extension) is applied.

The adhesive recommended by the manufacturer for the gauge was a Peekel quick-drying adhesive type L35 which requires skin cleansing with Benzene solution. After numerous tests, it was decided that clear surgical tape was an effective adhesive for proper skin fixation. This method was used for reasons of convenience.

The strain gauges were connected to a portable Wheatstone bridge (constructed by N. St. Pierre of

the Biomechanics Department). Each bridge accommodated two strain gauges and was operated either by a battery power source contained in the bridge or by drawing a 12-volt output power from the polygraph. For the more sensitive experiments, and to avoid polygraph noise, the battery source was employed.

The electromyography was recorded using silver-silver chloride electrodes (of a unity gain), preamplification units, and an "audio-oscilloscope"† Hewlett Packard EMG Unit Mark 1510B. The EMG output then was passed into an integrater (also constructed by Mr. N. St. Pierre) which converted the AC signals into their DC time-integral values. The integrater computed the area (definite integral) per unit of time between the original EMG-voltage ordinates and the time as an abscissa. The integrater also functioned as a rectifier and cut out small amplitudes below a specific threshold. Consequently, the spread of the EMG pattern was more pronounced because dominant signals were magnified and secondary redundant signals were eliminated. This is illustrated in Figure 2, which compares an ordinary one-lead ECG with its corresponding "integrated" ECG (I-ECG) recorded simultaneously over the same point on the subject's body by means of chrome plated snap electrodes. It is apparent that primarily the R-wave contributes to the time integral, and the influences of the other waves are small. Thus, in the inactive state of skeletal muscular activity, integrated electromyography (I-EMG) eliminated noise and was preferable for this research.

The strain gauge, the ECG, and the I-EMG pickups were all connected to a multi-channel Grass Polygraph. The highest sensitivity gain calibration was set on 0.01 mv/cm. The frequency gain settings during the experiments were 3 for the strain gauge measurements, 15 for the I-EMG, and 75 for the ECG.

†In our experiments, the audio channels were completely shut off (not used at all).

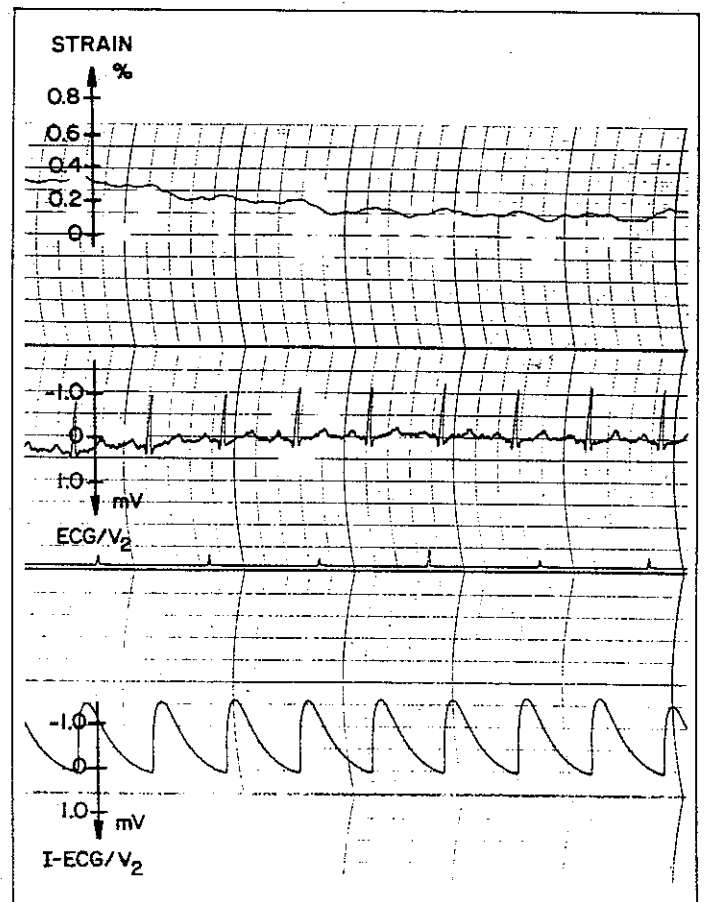
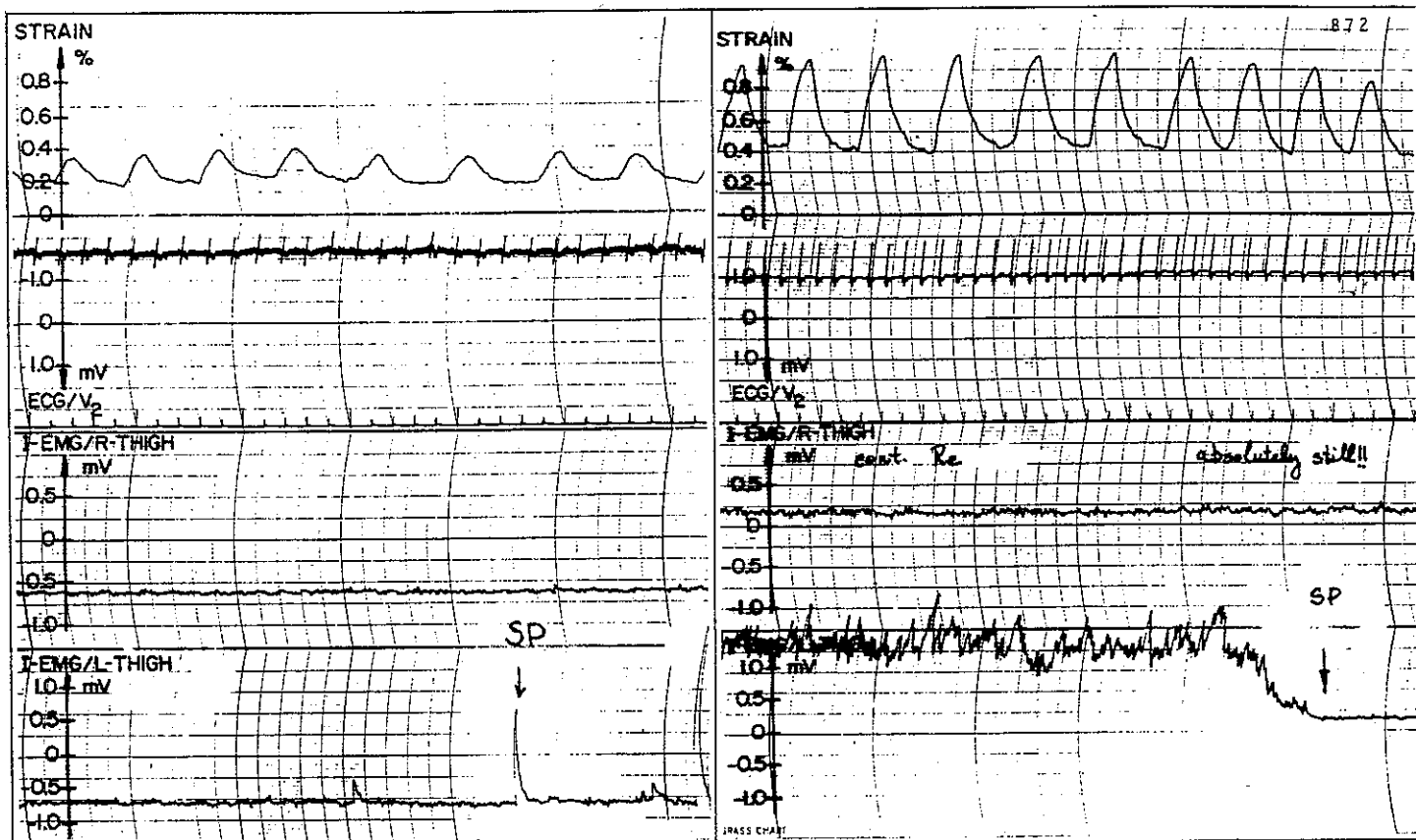


Fig. 2. Single lead ECG and I-ECG recorded simultaneously.

Results

Some typical four-channel recordings conducted during cranio-sacral manipulative procedures are shown in the following figures. Although each patient showed uniquely personalized patterns, there were repetitive features in all the tracings which allowed us to consider at least four different patterns



Figs. 3a and 3b. Mechano-electric pattern for a still point (SP) as (a) spike, and (b) absolute stop.

which all patients had in common. Using the classification suggested in Application Note 700 of Hewlett Packard, 1969, we labeled these patterns as follows: (1) *Rapid oscillations*. In the strainography (SG) over the left hypochondrium, these oscillations had a relatively small amplitude of 0.02-0.1 percent strain \ddagger and measured frequencies of 52-96 cycles per minute (cpm). They were present throughout

and, when correlated with the ECG, corresponded in a timely fashion with aortic expansion. In rare cases, the strain gauges also picked up what may have been the echo jerks of cardiac valve closures.

In the I-EMG tracings, the rapid oscillations with amplitudes of 0.1-0.2 mv. and measured frequencies of 52-96 cpm resulted from the fading cardiac electroactivity which was picked up on the thighs.

(2) *Transient waveforms*. These waveforms in the SG which possessed an amplitude of up to 3 percent strain and a frequency ranging from 6 to 30 cpm

\ddagger One percent strain means an extension of 1/100 of the original length of the gauge.

were in one-to-one correspondence with the respiratory rate (RR) (thoracic expansion). The average RR in the resting state ranged between 14 and 18 per minute in the majority of cases. In our study, trained athletes (karate experts) were able to voluntarily lower the RR to 6 per minute or less for 15 minutes or longer.

(3) *Rapid waveforms, or spikes.* Apart from the R-waveform in the ECG, and rarely in the SG, spikes were predominantly seen in the I-EMG. Spike amplitudes varied from 0.4 to 2.0 mv. The frequencies of spike occurrence seemed dependent upon the patient's neuromusculoskeletal pain syndrome. The appearance (frequency and amplitude) of spikes decreased with favorable response to the treatment and became a landmark of correlation between the physician's reported impressions and sensations and the patient's mechano-electric patterns.

(4) *Baseline changes.* These changes, primarily seen in I-EMG baseline, were either gradual or abrupt. Baseline changes often lasted for many seconds and then relaxed, abruptly forming the shape of a step function. They seemed to be correlated to changes in the patient's muscle tonus and/or reports of pain by the patient.

Specific terms were given to the physician-reported sensations during treatment. The following glossary was used:

(1) *Normal rhythm (NR).* This is a smooth regular pulsatile cranial activity in a rhythm of 8-12 cycles per minute. This rhythmic activity is in accord with the concept of a Cranial Rhythmic Impulse as put forth by Sutherland.^{1,3} The sensation of the normal rhythm as perceived by the physician is that of a uniform deformation of cranial vault shape, as its dimensions *reciprocally* and rhythmically change. This rhythmic effect can be sensed by palpation anywhere on the patient's body. The cause of this deformation is at present a subject for conjecture; however, it seems related to the fact that the dural compartment represents a semi-closed hydraulic

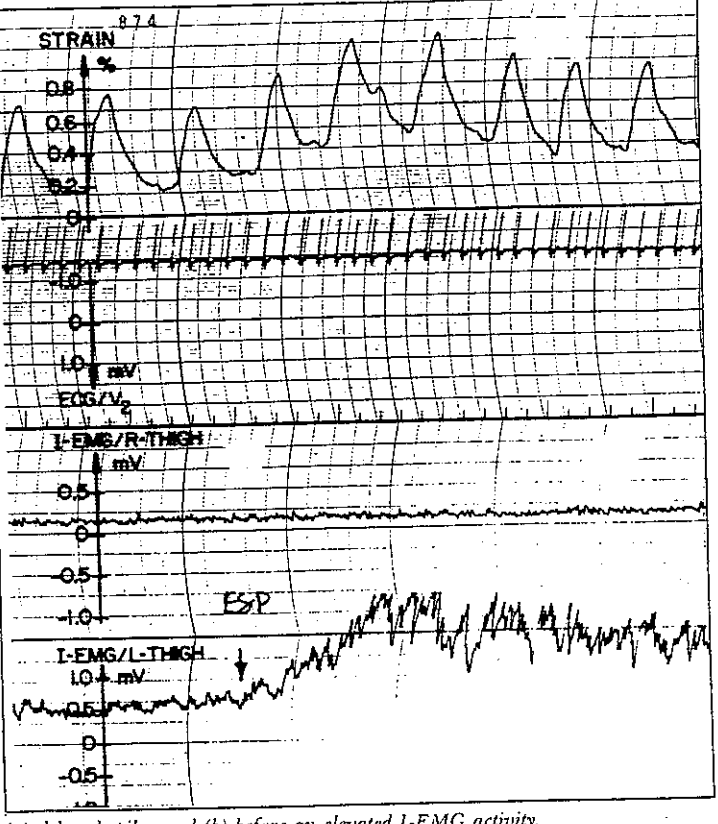
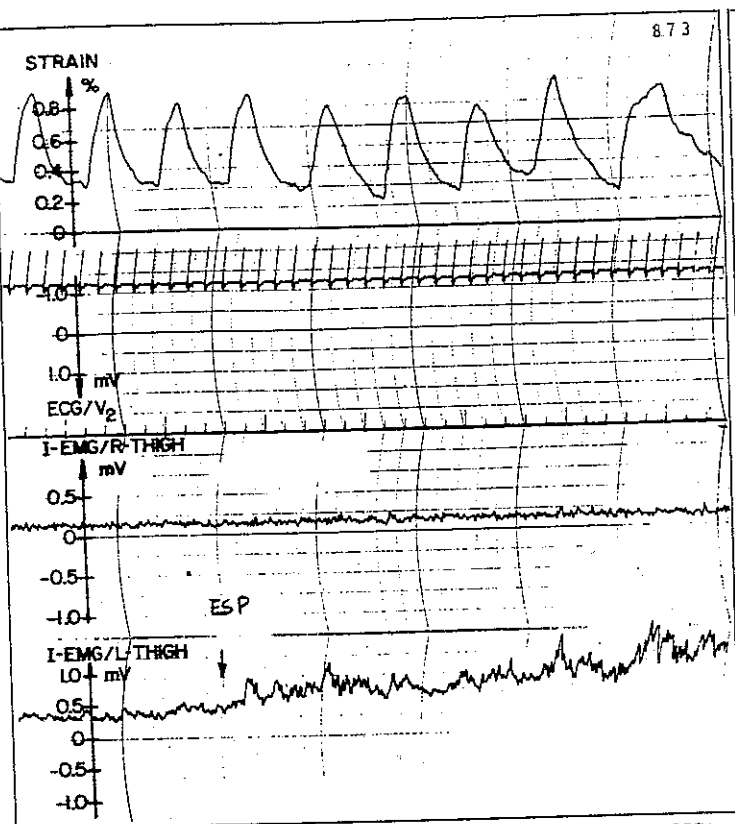
system as it extends from the cranium through the spinal canal to the sacrum. This normal rhythm was not seen on our I-EMG recordings taken during the experiments. There is, however, some strain-gauge pickup of the NR if the gauge is placed sufficiently close to the skull. (The investigators plan further work using strain gauges which will attempt to demonstrate the presence of a fluid wave motion.)

(2) *Still point (SP).*^{1,3} A still point is sensed when the normal rhythm stops temporarily. This cessation of motion might occur gradually as the rhythmic motion amplitude decreases. Or, it can take place suddenly when the zero point of the pulsatory waveform is attained, and the motion stops abruptly. On the I-EMG record over a thigh, an SP concurs with a short spike of 1.3 mv. (Fig. 3a) and with a drop to the baseline level if an absolute stop occurs (Fig. 3b).

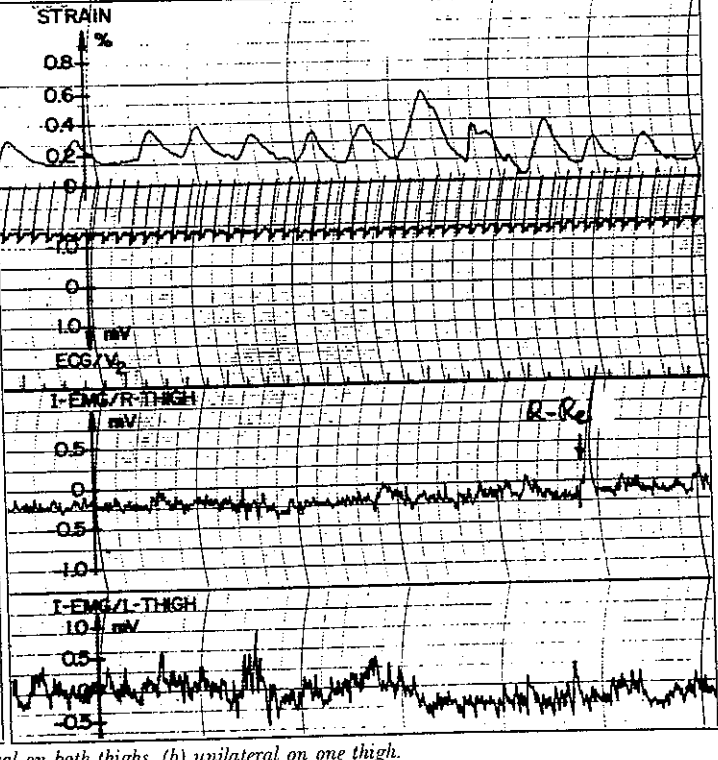
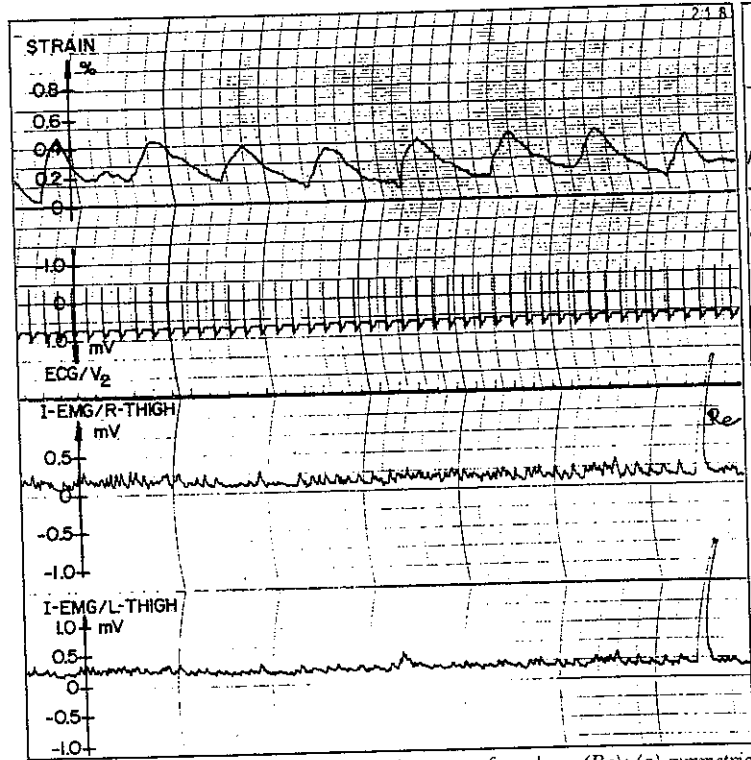
(3) *End of still point (ESP).*^{1,3} Following an SP, the system, both skull and body, seems to expand laterally. This phenomenon usually begins with long, slow expansion which then leads to a more even and symmetric motion. The ESP correlates on the thigh I-EMG record with the *delayed* appearance of a 0.4 mv. spike signal, the delay being of the order of 1 second (Fig. 4a). Furthermore, and in contrast to the SP, an elevated I-EMG activity takes place following the ESP (Fig. 4b).

(4) *Release (Re).* This sensation is of a "plastic" yielding of the volumetric container in the sense that frictional resistance or obstruction to fluidity have been overcome. This relaxation of resistance is accompanied by a sharp I-EMG spike which, in magnitude, surpasses any of the previously described spike patterns. The release signals can be symmetric (Fig. 5a) or unilateral (Fig. 5b). They play a paramount role in the osteopathic treatment as landmarks for improved functional activities.

(5) *Shifting.* The impression of a tidal fluid motion and change of direction of flow is sensed by the physician. For example, the feeling or perception



Figs. 4a and 4b. Mechano-electric pattern for end of still point (ESP) as (a) delayed spike, and (b) before an elevated I-EMG activity.



Figs. 5a and 5b. Mechano-electric pattern for release (Re): (a) symmetrical on both thighs, (b) unilateral on one thigh.

could be that of an uneven lateral expansion of the skull secondary to a volumetric fluid shift. When the direction of the fluid wave changes, a mechanical change takes place in concert with it.

The pattern of the mechano-electric changes in shifting is unique and unmistakable. The I-EMG shows a clear and distinct change of the baseline in the form of a step function. This usually takes place during the peak of respiratory inhalation while the pulmonary volume is maximal. This is clearly indicated by the strain gauge records (Figs. 6a and 6b). Our correlation between the sensation of shifting and the step-function patterns was 100 percent.

(6) *Pulsating*. This is a rapid oscillatory motion of low-amplitude and high-frequency (50-80 per minute) which is most commonly perceived in a localized area of the cranium. Generally, it precedes an ESP, a release, or a shifting. It is interpreted as an indication that some important mechanical change is about to occur. Pulsating usually occurs during the resting phase of the respiratory cycle (Fig. 7).

(7) *Wobbling*. This term was used to describe a low-mode (20-40 cpm), fluctuatory type of motion with amplitudes larger than those of "pulsating." Furthermore, the effect is not localized and can be felt over the body. Wobbling usually precedes a major release or shifting. The subjective impression of the physician is that of a braking mechanism which interferes with the fluid motion. The typical electromechanical pattern associated with wobbling is shown in Figure 8. This event takes place during the respiratory hold phase following inhalation.

(8) *Torsion*.** In torsion, the impression is that of a rotational periodic motion about a longitudinal axis through the patient's body where all sections of the body are not moving in synchrony. It is an asymmetric, distortional (not volumetric) type of a motion which is manifested as asymmetric I-EMG pickups on the lower extremities. Torsion is observed in Figure 9 as a series of spikes with modest amplitudes (0.7-1.0 mv.). It does not show in the respiratory

activity recordings.

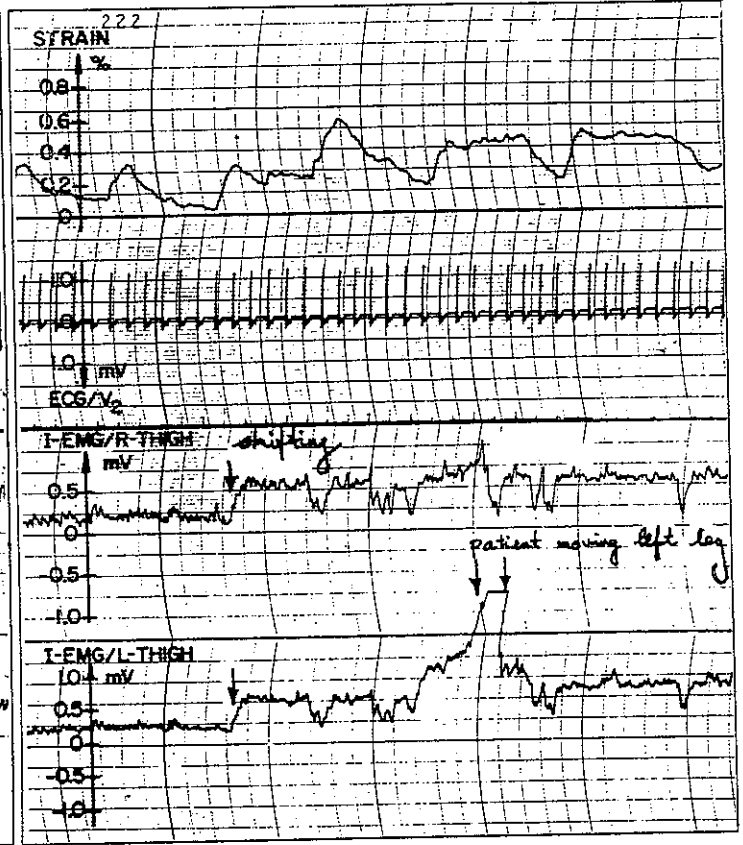
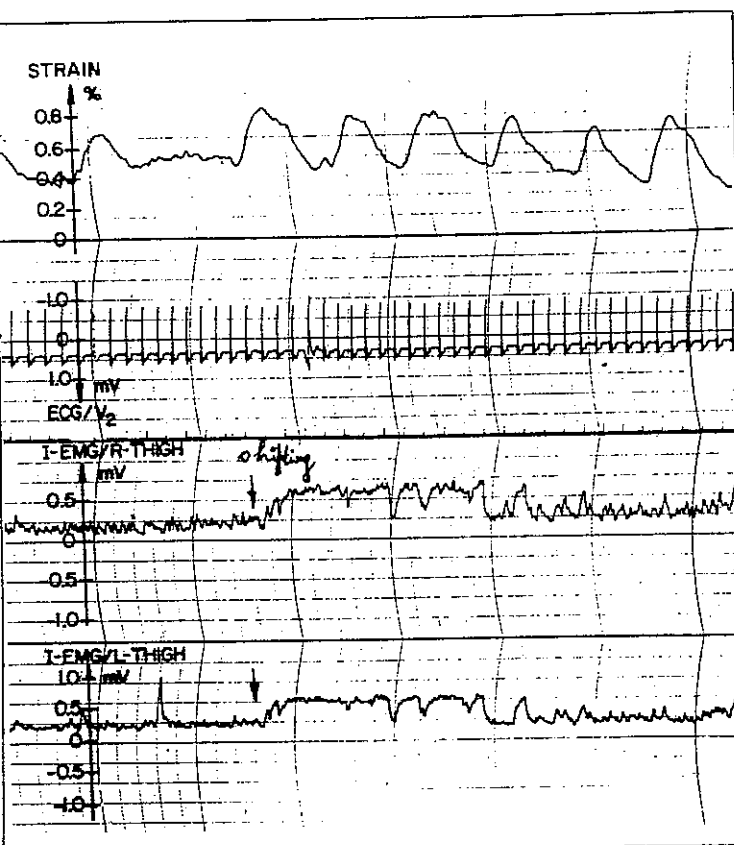
A common denominator of the above physician-reported sensations is that they are all passive or inherent to the patient's body; they all occur when the patient is in a relaxed and inactive state and when no gross manipulative treatment is being applied. They are most easily perceived or sensed when the patient is very quiet.

Discussion

It tacitly has been assumed throughout this presentation that the mechanical model underlying the impressions reported by the physician involved a fluid container composed of several physiologic compartments, each of which possessed uniquely different material properties. This container may allow for very slight changes in its volume capacity. In effect, and in accordance with the long accepted Monroe-Kellie doctrine,⁵ the relatively inelastic dura mater faithfully encloses the brain and spinal cord as a continuous and connected material region, || it may represent such a container.

|| The dura mater has been described as a tough inelastic membrane which forms the endosteum of the cranial vault. It attaches firmly about the entire circumference of the occipital foramen magnum. It then passes through the entire length of the spinal canal; its most firm attachments within the canal are only to the posterior aspects of the bodies of the second and third cervical vertebrae and within the sacral canal at the level of the second segment. It is separated from the spinal canal by the epidural space which ends at the second sacral segment (S-2). Below the level of S-2, the dura closely invests the filum terminale, passes through the sacral hiatus, and descends to the coccyx where it blends with the periosteum of that bone. The dura mater is connected to the dentate ligaments within the spinal canal, to the posterior longitudinal ligament, and to its nerve root sleeves which exit from the spinal canal with the spinal nerves. The restrictions to dural motion afforded by the latter three described attachments are much less than the restrictions imposed by those attachments within the cranial vault, at the foramen magnum at C-2 and C-3, within the sacral canal, and at the coccyx. The size of volume capacity of the dural container is much greater than is required to accommodate only the neural structures and, therefore, is quite able to respond somewhat independently to the stresses and pressures to which it is subjected. When considered as the material border of a fluid container with the previously described firm attachments to bone, the influence of these bony structures upon the mechanical forces within the container becomes quite apparent.

**Torsion as used in this research is not to be confused with "torsion" as an abnormal relationship between the sphenoid and occipital bones.^{1,3}



Figs. 6a and 6b. Mechano-electric pattern for shifting: (a) long duration, (b) short duration.

It is postulated that the contents of the dural container (brain, spinal cord, nerves, cerebrospinal fluid, blood, and other fluids) are very nearly incompressible.⁶ As a result, the combined volume of the contents of the dural container must be very nearly constant; and the volume of any one of its compartments can only be increased at the expense of the others.

The craniosacral osteopathic doctrine considers the major skull bones to be interconnected by visco-elastic sutures,⁷ acting as hinges about which a kinematic change in configuration can take place. Furthermore, because the dura mater is membra-

nous, it is susceptible to dynamic boundary changes which correlate to the physician's impression of the rhythmic and pulsatory motions of the cranial bones. The overall picture is, therefore, that of a less than rigid mechanical model with a fluid content, the motion of which, although small, is still within the range of sensory perception for trained craniosacral osteopathic physicians.

The nature of the mechanical craniosacral effect on the neuromusculoskeletal system is, unquestionably, obscure. However, the fact that the craniosacral system does have a measurable effect on other parts of the body has been demonstrated on an

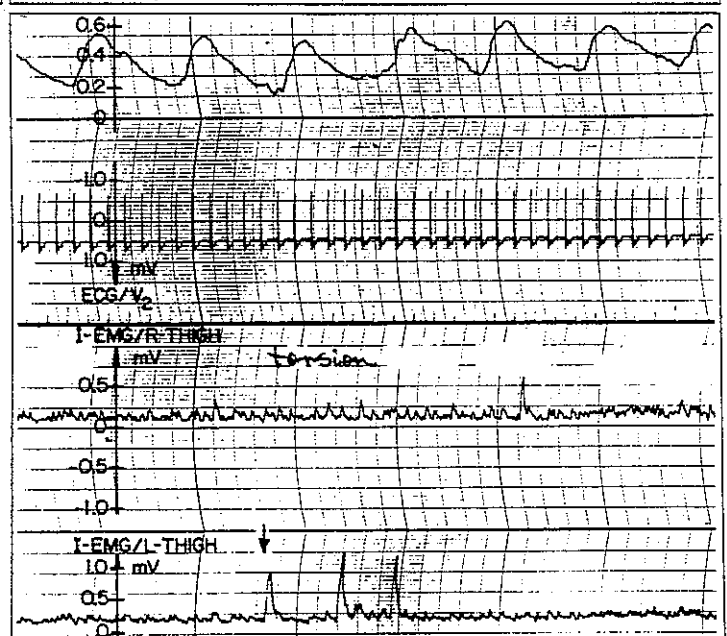
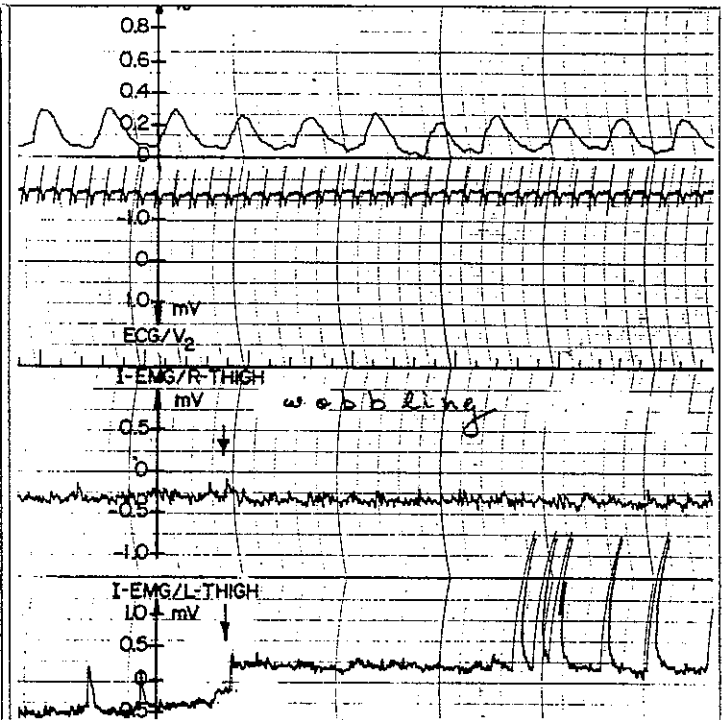
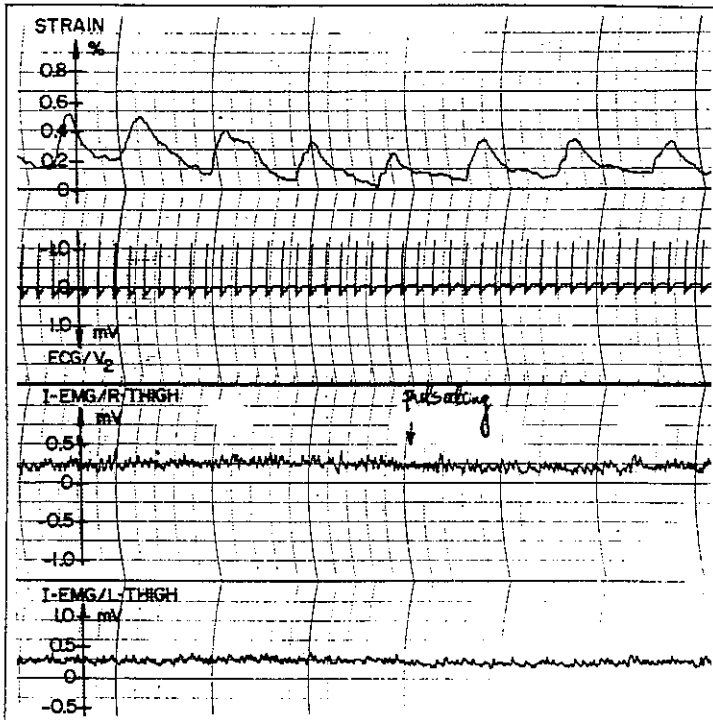


Fig. 7 (above). Mechano-electric pattern for pulsating. Fig. 8 (at right). Mechano-electric pattern for wobbling. Fig. 9 (at right below). Mechano-electric pattern for torsion.

input-output basis by this experiment.

Conclusions

Subjective impressions of various changes in the craniosacral mechanics which are reported by a trained craniosacral osteopathic physician are documentable by instrumental means. This documentation consists of changes in the bioelectric activity recorded by I-EMG from the lower extremities, ECG, and strain-gauge recordings of respiratory activity.

Specific patterns of the monitored mechano-electric parameters correlate directly with subjective

impressions of likewise specific changes in craniosacral mechanics as reported by the physician.

The range of the recorded integrated electromyographic signals is below the level of signals originating from any voluntary type of muscular activity, yet is by far larger than instrumental noise levels.

This research has been partly supported by the Department of Biomechanics, COM/MSU.

Appreciation is expressed to Drs. E. Retzlaff and R. Roppel for valuable suggestions and the use of equipment; to Mr. N. St. Pierre for technical assistance, and to Mr. J. Schulz from the Instructional Media Center, MSU, for the preparation of the figures.

1. Sutherland, W.A.: The cranial bowl. Free Press Company, Mankato, Minnesota, 1939
2. Wales, A.L.: The work of William Garner Sutherland. JAOA 71:788-93, May 72
3. Magoun, H.I.: Osteopathy in the cranial field. Journal Printing Co., Kirksville, Missouri, 1966
4. Karni, Z. and Polishuk, W.Z.: Multi-strain measurement of uterine activity. Proceedings of the 24th Annual Conference in Engineering in Medicine and Biology, 101, Nov. 71
5. Livingston, R.B., Woodbury, D.M., and Patterson, J.L. Jr.: Fluid compartments of the brain. Cerebral circulation. In Ruch, T.C., and Patton, H.D., Eds. Physiology and biophysics, W.B. Saunders Co., Philadelphia, 1965
6. Agarwal, G.C.: Fluid flow. A special case. In Brown, J.H.U., Jacobs, J.E., and Stark, L. Eds.: Biomedical Engineering, F.A. Davis Co., Philadelphia, 1971
7. Retzlaff, E., et al.: Sutural collagenous bundles and their innervation in Saimiri sciureus. Anat Rec 187:692, Apr 77

Accepted for publication in April 1978. Updating, as necessary, has been done by the authors.

Dr. Upledger is associate professor, Department of Biomechanics, Michigan State University—College of Osteopathic Medicine. At the time the paper was written, Dr. Karni was a visiting professor, Department of Biomechanics, MSU-COM. He is now a professor of biological engineering, Technion Institute, Haifa, Israel.

Dr. Upledger, College of Osteopathic Medicine—Michigan State University, Department of Biomechanics, East Lansing, Michigan 48824.