patterns have been palpated in the dog.[7]

Cranial motion has been attributed in part to forces associated with other processes (that is, respiratory movement) and transmitted up the vertebral column via its ligamentous attachments.[1] Figure 1 shows cranial bone displacements associated with respiration in support of that concept. Structural anomalies in the adult human skull, defined and described roentgenographically, show a correlation with sacral base lesions,[5] suggesting strain transmission via the connections of the vertebral column with the cranium. Our data (Fig. 3), which show that spinal flexions and extensions resulted in cranial bone displacement, support that hypothesis.

Summary

This report describes experiments designed to test the hypothesis that the cranial bones in the adult monkey move. Parietal bone displacement patterns were recorded. One corresponded to the respiratory frequency; another of 5-7 cycles · min.$^{-1}$ corresponded to neither heart rate nor changes in central venous pressure. Reversible displacement of the parietal bone was induced by the direct application of force to the cranium, by spinal flexion, and by spinal extension. A possible etiology for parietal bone displacement is discussed.

1. Sutherland, W.G.: The cranial bowl: Treatise relating to cranial articular mobility, cranial articular lesions, and cranial technic. W.G. Sutherland, Mankato, Minn., 1939. (Reprinted by the Osteopathic Cranial Association, Meridian, Idaho, 1948.)

2. Frymann, V.M.: A study of the rhythmic motions of the living cranium. JAOA 70:928-45, May 71

3. Scheckel, C.L., and Pazery, L.M.: Blood pressure of monkeys (Saimiri sciureus). Lab Primate Newsletter 1:18, 1962

4. Beischer, D.E., and Furry, D.E.: Saimiri sciureus as an experimental animal. Anat Rec 148:615-24, Apr 64

5. Greenman, P.E.: Roentgen findings in the craniosacral mechanism. JAOA 70:24-35, Sep 70

6. Wales, A.L.: The work of William Garner Sutherland, D.O., D.Sc. (Hon.). JAOA 71:788-93, May 72

7. Mitchell, F., Jr.: Personal communication, 1972

Supported in part by grants from the American Osteopathic Association and the Sutherland Cranial Teaching Foundation.

Cranial bone mobility

ERNEST W. RETZLAFF, PH.D.
DAVID K. MICHAEL, PH.D.
RICHARD M. ROPPEL, PH.D.
Michigan State University-College of Osteopathic Medicine
East Lansing, Michigan

The cranial bone mobility concept originated with observations by Sutherland[1] while he was a student of osteopathy at Kirksville in 1899. His studies on human skulls involving mobility at the sutures were accorded little acceptance until 1940, when the Academy of Applied Osteopathy offered its support. Then, in 1947, the Osteopathic Cranial Association was formed; in 1960, it became the Cranial Academy, an official affiliate of the AAO. The purposes of the Cranial Academy were to teach the techniques and to investigate the mechanisms of cranial manipulative therapy.[2]

Cranial bone articulations in the dissected skull suggest their mobility,[1,3,4] a generally accepted concept in the child and adolescent. However, many claim that adult cranial bone sutures are so completely ossified and the component bones are fused to such an extent that any movements of the individual bones relative to each other is a physical impossibility.[5-7]

The question of suture closure and ossification is discussed in most textbooks of anatomy. According to Gray[5] the time of suture closure varies considerably, with the final activity in old age. A point seldom discussed is what actually constitutes suture closure. Is it a complete ossification process, or are the interdigitated bone edges tied together by connective tissue?

The thirty-fifth British edition of "Gray's Anatomy"[8] shows a schematic representation of the general structure of the suture. The discussion of suture development presents numerous details which are not covered in most textbooks. One statement of particular interest is as follows:

> Sutural fusion does not even commence until the late twenties, proceeding slowly thereafter; yet it is clearly necessary that sutures should cease to function as mobile joints as rapidly as possible after birth.

It is difficult to rationalize why it is "clearly necessary" that the sutures cease to function as mobile joints. There is no

reason why the skull must become a solid encasement at any time; the same protective function would exist even if some mobility were retained.

In a recent report Magoun[9] stated that he does not agree that in the adult the skull bones are so completely fused that the cranium is a continuous shell-like structure enclosing the brain. He discusses the original hypothesis by Sutherland which maintains that, even though the bones may be firmly held together at the sutures, some degree of movement still is possible.

According to Ham,[10] the cranial bone sutures are classified as syndesmosis joints prior to their transformation to the synostosis type. The syndesmosis joint is one in which the surfaces of the bones are held together by connective tissue so that there will be limited movement of the bones. He further states that in the case of the cranial bones, the synostosis type joint is connected by bridgelike structures called wormian bone. Connective tissue is interspersed among these bone spicules. It may well be that Ham's classification of cranial bone sutures in the adult as synostosis joints is a matter of convenience rather than fact and that some degree of motion is possible because of the incompleteness of the suture closure by the wormian bone bridges.

It is apparent that the only way that these questions can be resolved is to perform well-controlled histologic studies on the cranial bone suture structure using animal tissues as well as materials obtained from human skulls in an approved manner. Pritchard, Scott, and Girgis[4] have already contributed some observations in this area, describing the sutural bond between adjacent bones as such that would allow slight movements while providing a bond of union for adjacent bones and permitting marginal expansion of bones during growth.

A recent report by Frymann[11] indicated that there is definite cranial bone movement in human beings which, in some instances, appears to be synchronous with heart and respiratory activity. She also describes a third type of skull bone movement characterized by slow waves which seem to be independent of the other two physiologic processes. Frymann postulates that this third type of movement may be connected to the activity of the medullary respiratory center neurons or to motor neuron membrane potentials by a common origin. Other possible mechanisms could result in this third type of wave, for example, changes in the cerebrospinal fluid pressures.

We have undertaken a series of studies to re-evaluate the various concepts involved in cranial osteopathy. It was decided that the first study would be to determine whether or not the parietal bones in the squirrel monkey move spontaneously and whether this movement, if present, is related to the activity of the heart, the respiratory system, or to some other physiologic events. (A preliminary study on parietal bone displacement in response to force in the squirrel monkey has also been reported in this issue.[2]) A second question to be answered was whether or not induced cerebrospinal fluid pressure changes could cause cranial bone movement.

Methods

These experiments were performed using anesthetized, adult, female squirrel monkeys, Saimiri sciureus. The head of the monkey was immobilized by means of a stereotaxic instrument.

Skull movement was measured by use of force displacement transducers attached to a small screw-eye screwed into the approximate midpoint of the left and right parietal bones. Blood pressure and respiration were monitored by direct vessel and tracheal cannulation in conjunction with appropriate transducers. Recording was by means of a four-channel Grass polygraph. Additional details of the experimental methods are presented in the accompanying paper by David Michael, PH.D., and Ernest Retzlaff, PH.D.[12]

Results

Recordings from the first monkey, shown as Figure 1, demonstrate the activity of the parietal bones when the head is *not* firmly fixed, but only loosely mounted in the head holder of the stereotaxic apparatus. In this case the activity of both respiratory and cardiac systems are reflected in the recorded activity of movement in each of the parietal bones. The respiratory cycle and the slow wave recorded from the skull bones show a definite one-to-one ratio. There also is a fast oscillatory type wave superimposed on the slow wave; this is a reflection of the cardiac activity.

Figure 2 shows a change in the recorded activity of the two parietal bones. In this instance the head is more firmly fixed than before. The right parietal bone movement, slow wave, seems to be nearly synchronous with the respiratory system activity. The left parietal bone activity is

continued on page **871**/144

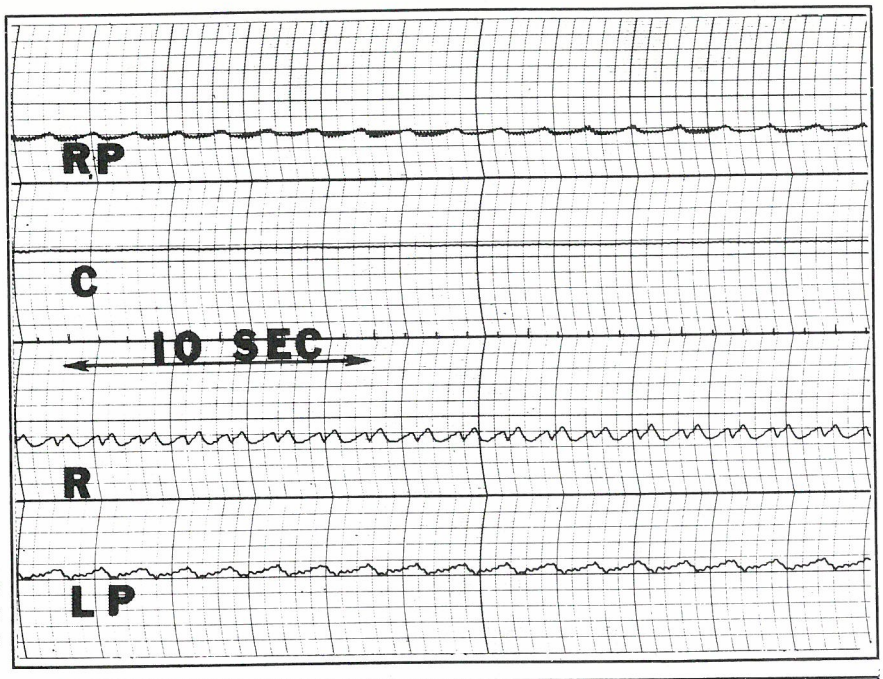

Fig. 1. *Respiratory (R) and cardiac (C) system activity reflected in both right parietal (RP) and left parietal (LP) bone movement. This activity occurs when head is loosely mounted in the stereotaxic apparatus.*

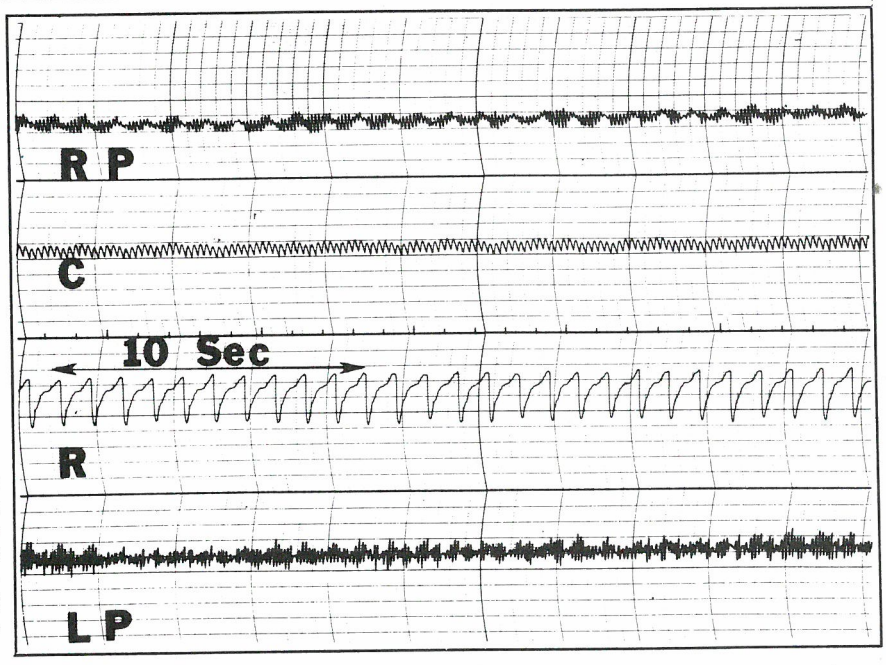

Fig. 2. *Recorded activity of parietal bones when head is partly immobilized. Note that the right parietal bone (RP) movement nearly follows the respiratory system (R) pattern, while the left parietal bone (LP) has a more independent movement pattern. The superimposed oscillatory fast wave does not reflect the cardiac system (C) activity.*

independent of both the respiratory system activity and the movements of the right parietal bone. The fast oscillatory waves occur at a rate nearly two times that of the cardiac activity.

Figure 3 is a typical recording of the right and left parietal bone movement when the head is firmly secured in the stereotaxic holder. Each of the two parietal bones displays its own slow wave frequency with a superimposed fast oscillatory wave pattern. In this case the fast wave is an indication of some activity that differs from that of the cardiac system.

Figure 4 demonstrates the effect of altering the cerebrospinal fluid pressure by flexing and extending the body of the monkey. The increased amplitude of both the slow and fast waves occurs only while the body is flexed and extended. The left side of the record shows what happens when the body movement is stopped.

Discussion and conclusions

These experimental results support the idea that there is more than one type of spontaneous cranial bone movement in the adult squirrel monkey. One pattern of movement is directly related to the activity of the respiratory and cardiac systems. This activity is characterized by a slow wave, which is synchronized with each respiratory cycle. Superimposed on this slow wave is a rapid oscillatory wave, which is a direct reflection of the cardiac system activity. This pattern of parietal bone movement is seen when the monkey's head is permitted to move freely in the stereotaxic head holder.

When the head is immobilized to an extent that allows limited movement, each of the parietal bones assumes its own frequency pattern of movement. This observation supports the concept of free movement of the various cranial bones. In this instance the rapid oscillatory wave

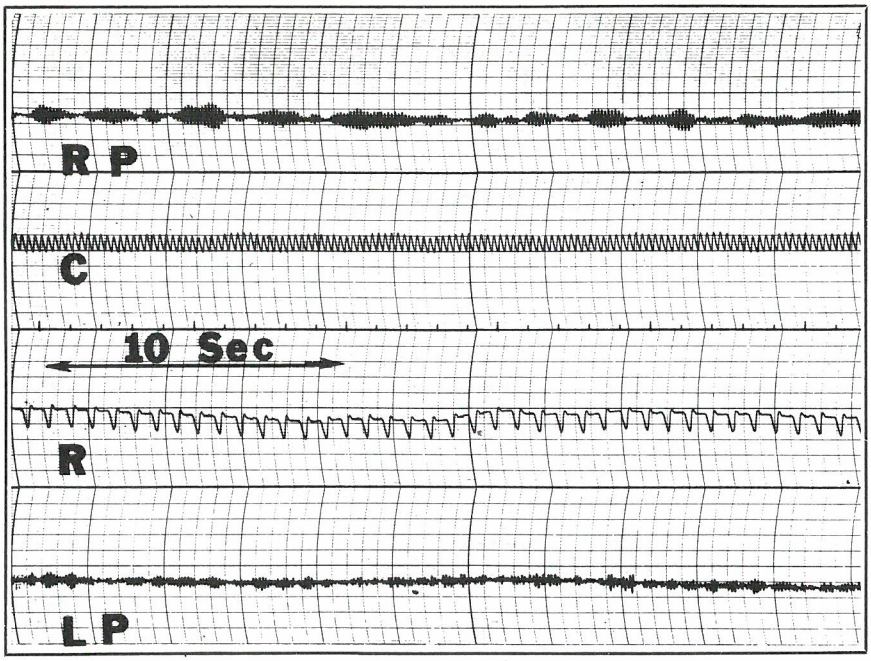

Fig. 3. *When the monkey's head is firmly fixed in the stereotaxic holder, via the temporal and facial bones, both the right parietal (RP) and left parietal (LP) bones move independently.*

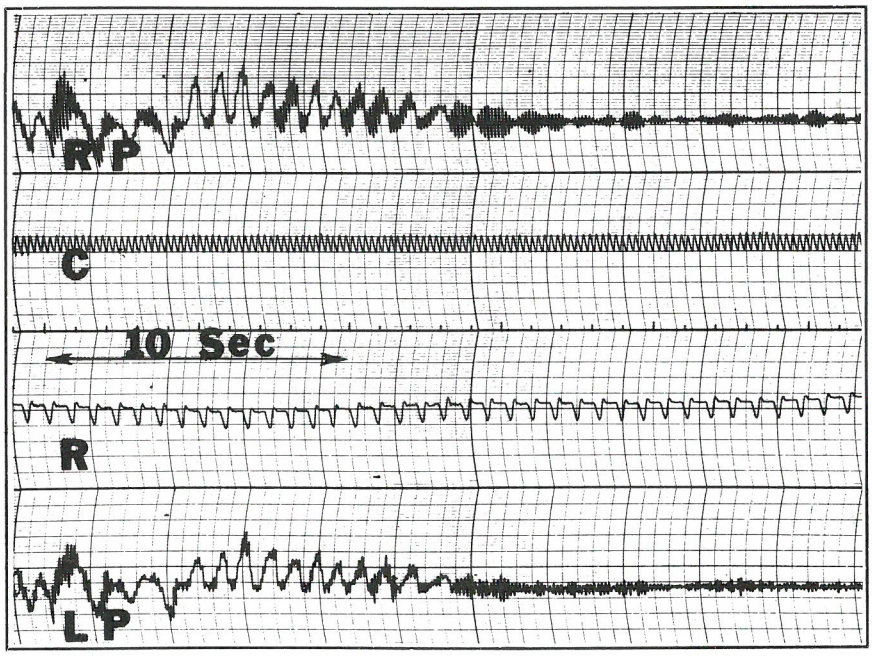

Fig. 4. *Vertebral column flexion and extension is reflected in movements of both the right parietal (RP) and left parietal (LP) bones. This is shown on left half of record. When the induced movement is stopped, the parietal bones resume their rhythmic movement pattern.*

occurs at a rate different from that of the cardiac system.

Complete immobilization of the head via the temporal and facial bones, as described earlier,[2] results in a parietal bone movement pattern that is independent of the respiratory and cardiac systems. Each side displays its own frequency of movement, a feature which suggests that the bones move independently and that a force such as that which arises from alterations in the cerebrospinal fluid pressure moves the parietal bones.

Support for the idea that changes in the cerebrospinal fluid pressure cause the bones to move was obtained from the procedure which involved flexing and extending the monkey's vertebral column. These maneuvers caused both the slow wave and the fast oscillatory waves to increase in amplitude. The one-to-one ratio of the vertebral column movement and the parietal bone movement indicated that alterations in the cerebrospinal fluid pressure are responsible for the bone movement. When the flexion-extension procedure was stopped, the parietal bones assumed their former spontaneous rhythmic activity pattern.

These experimental results support Sutherland's theory of cranial bone movement and the belief that cerebrospinal fluid pressure changes are responsible for the spontaneous bone movement.

Summary

As a part of a study of the mechanisms involved in cranial manipulative therapy, it was first necessary to establish whether the individual bones can move and second, to determine what physiologic forces are involved. The movement of the parietal bones of the anesthetized squirrel monkey were recorded along with simultaneous recording of respiration and cardiac activity.

The results obtained support the idea that when the animal's head is *not* firmly fixed, both respiratory and cardiac activity are reflected in the recordings made of the bone movement. When the head is firmly secured in the stereotaxic holder via the temporal and facial bones, an additional slower bone movement pattern can be recorded from the parietal bones. This movement is not related to respiration or cardiac activity.

It also was found that flexion and extension of the vertebral column caused the parietal bones to move in a one-to-one relationship with the induced movement. We propose that this third type of slow movement is caused by changes in the cerebrospinal fluid pressure and that it may occur as a normal physiologic event.

1. Sutherland, W.G.: The cranial bowl: Treatise relating to cranial articular mobility, cranial articular lesions, and cranial technic. W.G. Sutherland, Mankato, Minn., 1939. (Reprinted by the Osteopathic Cranial Association, Meridian, Idaho, 1948.)

2. Magoun, H.I.: Osteopathy in the cranial field. Ed. 2. Journal Printing Co., Kirksville, Mo., 1966

3. Kahn, F.: Man in structure and function. Translated and edited by G. Rosen. Vol. 1. A.A. Knopf, Inc., New York, 1943

4. Pritchard, J.J., Scott, J.H., and Girgis, F.G.: Structure and development of cranial and facial sutures. J Anat 90:73-86, Jan 56

5. Gray, H.: Anatomy of the human body. Edited by C.M. Goss, Ed. 29 (Amer.). Lea and Febiger, Philadelphia, 1973

6. Hamilton, W.J., Boyd, J.D., and Mossman, H.W.: Human embryology: Prenatal development of form and function. Ed. 4. Williams and Wilkins Co., Baltimore, 1972

7. Lockhart, R.D., Hamilton, G.F., and Fyfe, F.W.: Anatomy of the human body. J.B. Lippincott Co., Philadelphia, 1959.

8. Gray, R.: Anatomy of the human body. Edited by R. Warwick and P.L. Williams. Ed. 35 (Brit.). W.B. Saunders Co., Philadelphia, 1973, p. 389

9. Magoun, H.I.: Newer knowledge of the skull. JAOA 73:250-2, Dec 73

10. Ham, A.W.: Histology. Ed. 6. J.B. Lippincott Co., Philadelphia, 1969

11. Frymann, V.M.: A study of the rhythmic motions of the living cranium. JAOA 70:928-45, May 71

12. Michael, D.K., and Retzlaff, E.W.: A preliminary study of cranial bone movement in the squirrel monkey. JAOA this issue

Supported in part by grants from the American Osteopathic Association and the Sutherland Cranial Teaching Foundation.